

AperTO - Archivio Istituzionale Open Access dell'Università di Torino

Overexpression of histamine H4 receptors in the kidney of diabetic rat

This is the author's manuscript

Original Citation:

Availability:

This version is available <http://hdl.handle.net/2318/129125> since 2016-11-11T15:37:00Z

Published version:

DOI:10.1007/s00011-012-0587-7

Terms of use:

Open Access

Anyone can freely access the full text of works made available as "Open Access". Works made available under a Creative Commons license can be used according to the terms and conditions of said license. Use of all other works requires consent of the right holder (author or publisher) if not exempted from copyright protection by the applicable law.

(Article begins on next page)



UNIVERSITÀ DEGLI STUDI DI TORINO

The final publication is available at Springer via [http://dx.doi.org/doi: 10.1007/s00011-012-0587-7](http://dx.doi.org/doi:10.1007/s00011-012-0587-7)

Overexpression of histamine H₄ receptors in the kidney of diabetic rat

Rosa A.C.¹, Grange C.², Pini A.³, Katebe M.A.⁴, Benetti E.¹, Collino M.¹, Miglio G.¹, Bani D.³, Camussi G.², Chazot P.L.⁴ and Fantozzi R.¹

¹Dipartimento di Scienza e Tecnologia del Farmaco, Università di Torino, Turin, Italy

²Department of Internal Medicine, Centre for Molecular Biotechnology and Centre for Research in Experimental Medicine (CeRMS), Torino, Italy

³Department of Anatomy, Histology and Forensic Medicine, Section of Histology, University of Florence, Florence, Italy

⁴School of Biological and Biomedical Sciences and Wolfson Research Institute, Durham University, Durham, UK

Running title: Histamine H₄ receptors kidney expression

Correspondence: Paul L Chazot, PhD,

School of Biological and Biomedical Sciences & Wolfson Research Institute,

Durham University,

South Road,

Durham DH1 3LE, UK

Phone: +44 191 33 41305

Fax: +44 191 334 1201

e-mail: paul.chazot@durham.ac.uk

Abstract

Objective and design: The renal expression of H₁ and H₂ receptors was previously demonstrated, while that of the H₄ receptor **has been** poorly investigated, thus the aim of this research was to investigate the expression of the H₄ receptor in the kidney of diabetic rats.

Material or subjects: 24 8-week-old male Wistar rats

Treatment: Diabetes was induced in 12 rats by a single i.v. injection of streptozotocin, and animals were sacrificed 6 weeks later.

Methods: Kidneys were collected and processed for quantitative PCR or immunohistochemical analyses. To ascertain the renal topology of the H₄ receptor, colocalization experiments were performed **with a series of markers**.

Results: H₄ receptor is expressed in healthy rats, although at a very low level, and is profoundly upregulated in diabetic animals. Immunohistochemical **analysis** revealed the highest immune-positivity in the medulla. Colocalization experiments revealed a close overlap in expression topology of **the** H₄ receptor and both Tamm-Horsfall glycoprotein and aquaporin 1 was observed.

Conclusions: The results demonstrate, **for the first time, that the H₄ receptor** is expressed in the kidney mainly by resident renal cells of the loop of Henlé and that this receptor is significantly overexpressed in diabetic animals, thus suggesting a possible role in the pathogenesis of **diabetes**-associated renal disease.

Keywords Histamine, histamine H₄ receptor, diabetes, kidney, loop of Henlé

Histamine is a biogenic amine that exerts many (patho)physiological effects through its interaction with four subtypes of G-protein-coupled receptors, designated H₁₋₄, which are differentially expressed in various tissues and cell types. It is synthesized from L-histidine through the catalytic activity of the rate-limiting enzyme histidine decarboxylase (HDC). Although HDC is principally expressed in mast cells, the most important source of histamine, it is well recognized that a number of other cell types, such as tuberomammillary nucleus (TMN) neurons in the brain and parietal cells in the stomach [1], also express this enzyme. Notably, HDC expression has been also reported in the kidney, where it was found in the proximal tubule [2], thus in keeping with the demonstrated ability of the kidney to produce histamine.

In particular, in humans the renal histamine content markedly exceeds plasma levels ($<10^{-8}$ M in plasma vs $\approx 10^{-6}$ M in glomeruli) [3]. Indirect demonstrations sustain the hypothesis that histamine could be involved in renal pathophysiology in humans. In fact, it was demonstrated in healthy subjects that loading doses of L-histidine led to an increase in histamine concentration in urine, but not in blood [4], and that urinary and blood levels of histamine are elevated following renal transplantation [5].

Some studies suggest that histamine may be involved in **diabetes**-related kidney disease. Studies performed in streptozotocin (STZ) diabetic rats have shown, consistently with a generalized effect of diabetes on inducing an increase in histamine, a greater content of histamine in the kidney of diabetic animals than that of controls [6, 7]. This increase has been related to a significantly greater tissue HDC activity of diabetic rats than controls without a concomitant decrease in histaminase activity [8], an enzyme that catalyzes the inactivation of histamine. Besides, it has been suggested that renal histamine may represent one triggering stimulus for the functional microangiopathy in diabetes mellitus, **which** may lead to the development of diabetic nephropathy. In fact, it has been reported, in rats, that histamine reduces the ultrafiltration coefficient [9]. These data are in keeping with more recent studies aimed to assess the role of mast cells in the kidney. It is well recognized that in **the** normal kidney, mast cells are constitutively present **at low numbers**. However, their density and activation increase in the renal cortical **tubulointerstitium** and in the periglomerular and perivascular area, but not in glomeruli, in a variety of human renal diseases, including diabetic nephropathy [10-12].

Hitherto, the renal effects of histamine have been related to the activation of H₁ and H₂ receptor, both identified in the glomeruli [3, 13], while the H₄ receptor expression in the kidney was poorly investigated. A very low level of H₄ receptor mRNA has been reported in the kidney of dog, monkey, rat, mouse, guinea pig and pig [14-18]. Despite the **demonstration** of an increasing histamine release in diabetic kidney, there is no evidence for the involvement of H₄ receptor expression in the **diabetes**-related kidney disease. Thus, in order to gain further insight into the histamine signal in the diabetic kidney, the aim of this pilot study was to investigate the expression of the H₄ receptors in the kidney of diabetic rats **with severe** hyperglycemia.

Materials and methods

Animals and protocols

Male 8-week-old Wistar rats (Harlan–Italy, Udine, Italy) were provided with a Piccioni pellet diet (No. 48; Gessate Milanese, Italy) and water *ad libitum*. Animal care was in compliance with Italian regulations on the protection of animals used for experimental and other scientific purposes (D.M. 116/92). The experimental protocol was approved by the Turin University Ethics Committee for the animal use.

Diabetes induction

Insulinopenic diabetes was induced by a single intravenous tail vein injection of streptozotocin (STZ; 50 mg/kg) diluted in citrate buffer 0.1 M (pH 4.0) in accordance to the literature (Wu and Huan, 2008). Rats were randomised into two groups: (1) non-diabetic animals (n = 12) and (2) diabetic animals (n = 12). A blood sample was collected 4 days after the STZ injection, and plasma glucose was determined using a glucose analyzer (Accu-Chek Compact System; Roche Diagnostics, Basel, Switzerland). Diabetes was defined by a blood glucose level of > 300 mg/dl. Six weeks after induction of diabetes, when experimental rats reached a blood glucose level > 300 mg/dl (severe hyperglycemia), rodents were weighed and placed in metabolism cages to collect 24 h urine. Animals were killed after aortic exsanguination under anaesthesia by ip injection (30 mg/kg) of Zoletil 100 (15 mg/kg tiletamine + 15 mg/kg zolazepam; 100 mg/ml; Laboratoires Virbac, France). Blood samples were stored at –80°C. Kidneys were isolated, weighed and processed for biochemical or histological evaluation according to standard procedures by rapidly freeze-clamping with liquid nitrogen and stored at –80 °C or fixing in 4% paraformaldehyde solution overnight, respectively.

Measurement of biochemical and histological parameters

Serum and urine creatinine concentrations were measured spectrophotometrically at 490 nm by the Jaffé kinetic reaction (Schlatzer et al., 2009), using commercially available kits (Cat. Nos. KB02-H1, K002-H1; DetectX, Arbor Assays, MI, USA). Renal creatinine clearance was calculated by the standard formula $C = (U \times V) / P$, where U is the concentration in urine, V is urine flow rate, and P is the plasma concentration. Creatinine concentrations and creatinine clearance were used as indicators of impaired renal function, whereas N-Acetyl-β-glucosaminidase (NAG), measured in the urine by a colorimetric assay (Roche Diagnostics), was used as a marker of tubular injury [19].

Histological sections, 5 μm thick, were cut from the paraffin-embedded kidney samples. Tissue sections were stained with periodic acid-Schiff (PAS) in a single session to minimize artifactual differences in the staining. Photomicrographs of the histological slides were randomly taken with a digital camera connected to a light microscope equipped with a x40 objective. In total, 10 images and 60 glomeruli from each rat were examined by two independent investigators blinded to the experimental group.

RT-PCR and quantitative real-time PCR analysis

The analyses were performed as previously described [20]. Briefly, RT-PCR amplifications were performed in 25 µl reaction mixtures containing 1.0 µl of cDNA, 2.5 µl of 10× buffer, 1.0 µl of 50 mM MgCl₂, 0.20 µl of 25 mM dNTPs mix, 0.05 U of EuroTaq DNA polymerase (Euroclone, Milan, Italy), and 2.5 nM of sequence-specific oligonucleotide primers (Sigma-Genosys, Milan Italy): *H4R* (147 bp) forward 5'-TGCCAGCTTCTGTCTCTGTC-3', reverse 5'-ACTGCTGTTGGCTCGTGTTC-3'; *18S* (489 bp) forward 5'-TCAAGAACGAAAGTCGAAGGT-3', reverse 5'-GGACATCTAAGGGCATCACAG-3'. PCR amplicons were resolved in an ethidium bromide-stained agarose gel (3%) by electrophoresis, and signals were quantified using NIH ImageJ 1.41 software. *18S* gene expression was used as an internal control. Real-time PCR experiments were performed in 25 µl reaction mixtures containing 10 ng of cDNA template, Power SYBR® Green PCR Master Mix and AmpliTaq Gold® DNA Polymerase LD (Applied Biosystems, Inc., Foster City, CA, USA), was directed to detect and quantify *H₄ receptor mRNA*. Relative quantification of the products was performed using a 48-well StepOne™ Real Time System (Applied Biosystems). For all real-time PCR analyses, *18S* mRNA was used to normalize RNA inputs.

Antibodies

H₄ receptor was detected by using the anti-h*H₄* receptor (374-390) antibodies produced and validated for detecting both human and rodent *H₄* receptors in the School of Biological and Biomedical Sciences, Durham University [21-27]. Briefly, the antibody was generated against the last 17 amino acids of the C-terminal tail of the *H₄* receptor conjugating the peptide corresponding to the amino acids CIKKQPLPSQHSRSVSS to thyroglobulin by the cysteine-coupling method [28]. The resultant conjugate was used to generate polyclonal antibodies in rabbits as previously described [29]. The selectivity of the anti-h *H₄* receptor antibody was confirmed by blockade with the C-terminal peptide of the *H₄* receptor and a lack of cross reactivity with the human *H₃* receptor, the most related G-coupled receptor [26].

For comparison, a commercial available anti-*H₄* receptor (Y-19; sc-33967 Santa Cruz Biotechnology, Inc., Santa Cruz, CA, USA) was also employed. The antibodies for renal markers, aquaporin (AQP)1, AQP2, Na-K-Cl cotransporter (NKCC)1, Tissue non-specific alkaline phosphatase (TNAP) and Tamm-Horsfall glycoprotein (THP), were purchased from Santa Cruz Biotechnology, Inc.; while the secondary biotinylated anti-rabbit and anti-goat antibodies were from Vector Laboratories, Inc. (Burlingame, CA, USA) and the secondary Alexa Fluor-488 anti-goat or Alexa Fluor-594 anti-rabbit polyclonal antibodies were from Molecular Probes (Leiden, the Netherlands).

Immunohistochemistry

Conventional immunohistochemical procedures were employed as described previously [30, 31]. Briefly, immunoperoxidase staining for *H₄* receptor, AQP1, AQP2, NKCC1, TNAP and THP, was performed on 5 µm sections for formalin-fixed tissue using an appropriate antigen retrieval (sodium citrate 50 mM pH 8.4 for 30 min at room

temperature followed by sodium citrate 50 mM pH 8.4 for 30 min at 80°C for the anti-hH₄ receptor (374-390); or sodium citrate 10 mM pH 6.9 for 3 cycles of 20 s in microwave 750 W for the anti-H₄ receptor (Y-19)); sections were incubated overnight with anti-hH₄ receptor (374-390) or anti-H₄ receptor (Y-19) (2 µg/ml) or anti-AQP1, -AQP2, -AQP3, -NKCC1, -TNAP and -THP (4 µg/ml) at 4°C, followed by a three-layer streptavidin–biotin–peroxidase complex staining method (Vectastain ABC Elite kit and 3',3'-diaminobenzadine tetrahydrochloride, DAB; Vector Laboratories, Inc.). Tissue was also screened in the absence of primary antibody. In all cases, a major part of the staining elicited by the untreated antibody was abolished. All sections were stained or immunostained in a single session to minimize artifactual differences in the staining. Photomicrographs of the histological slides were randomly taken with a digital camera connected to a light microscope equipped with a ×40 objective (Leica DM750).

Immunofluorescence and confocal analysis

After antigen retrieval and blocking, 5 µm kidney paraffin sections were incubated with primary anti-H₄ receptor and anti-THP or -AQP1 antibodies, followed by incubation with Alexa Fluor-488 anti-goat or Alexa Fluor-594 anti-rabbit polyclonal antibodies. After counterstaining with DAPI, photomicrographs were obtained by a confocal laser-scanning microscope LSM-510 microscope equipped with a ×40 objective (Carl Zeiss, Oberkochen, Germany).

Image Analysis

Images were processed by ImageJ 1.41 (NIH, USA) software and quantified using the Color Deconvolution image analysis tool as previously described [30-33]. Briefly, H₄ staining defined by diaminobenzidine were colour deconvoluted from counter-stained sections. A threshold was chosen for identifying H₄ positive staining areas and used on all slides in the study without modification. The percentage area was calculated for H₄ positive tissue. Values are means ± S.E.M. of the OD (in arbitrary units) measurements of individual rats (ten images/zone each) from the different experimental groups.

Data analysis

Results are shown as means ± SEM and were analysed by Student's t-test or one-way ANOVA with Dunnett's multiple comparison and Student–Newman–Keuls tests were used to determine significant differences between means: *p*-values less than 0.05 were considered significant. Data analysis assumed normality, using Prism 4 software from Graphpad (CA, USA).

Results

Pathophysiology and renal histology

As shown in Table 1, in comparison to controls, body weight was reduced and blood glucose level was increased in diabetic rats. The kidney-to-body weight ratio was significantly higher, thus suggesting an organ hypertrophy. The

creatinine clearance was significantly decreased. The increase in urinary NAG level suggested tubular dysfunction (Table 1). Consistently, these biochemical abnormalities were associated with clear changes in renal histology. Using PAS staining, histological analysis of kidney sections from the diabetic animals showed severe tubular alterations and moderate glomerular modifications. In fact, in comparison to controls, STZ-treated rats revealed interstitial space increase and marked tubular degeneration associated with robust tubular epithelial cells loss and decreased PAS positivity of the brush-border membranes (Figure 1a and 1b). Moreover, the glomeruli of diabetic rats displayed moderate capsular fibrosis and tuft-to-capsule adhesion, with capillary dilatation and mild mesangial matrix expansion (Figure 1c and 1d).

Renal H₄ receptor expression in diabetic rats

In control rats the H₄ receptor gene was constitutively expressed, although unevenly and at a very low level (Figure 2a). In contrast, a higher expression level was detected in STZ-treated animals (Figure 2b). The PCR data were confirmed by immunohistochemical analysis (Figure 3). In particular, while there was very weak H₄ receptor-like immunoreactivity in control rats, a high level of labelled cells in both medulla and cortex of diabetic animals was observed. In contrast, in the papilla the immunoreactivity was generally very low. Interestingly, H₄ receptor-like immunoreactivity was not detectable in the glomeruli. This observation was confirmed using a quantitative image analysis, performed with the Color Deconvolution image analysis tool. As shown in Figure 4 the calculated percent area for the H₄ receptor-like immunoreactivity was significantly higher in the medulla, while the papilla showed modest DAB positivity. These results were obtained by using the anti-hH₄ receptor (374-390) antibody. Comparable results were observed with the commercially available anti-H₄ receptor (Y-19). The similar results validate the use of the anti-hH₄ receptor (374-390) antibody to detect the H₄ receptor in the rat kidney.

H₄ receptor cellular localization

The above data, indicating a higher H₄ receptor-like immunoreactivity in the medulla, suggest a tubular expression of the receptor. Thus, we have performed sequential section staining with different tubular cells markers to distinguish between the different portions of the nephron. When H₄ receptor immunostaining was compared to individual tubular cell markers, a close overlap in expression topology was suggested with the markers of the loop of Henlé (Online Resource 2). To confirm and refine this result immunofluorescence staining and confocal analysis was performed with both THP, marker of the thick ascending limb of the loop of Henlé, and AQP-1, marker of both the proximal tubules, the thin descending limb of the loop of Henlé and also expressed on some walls of microvessels. As shown in Figure 5, H₄ receptor colocalizes with both THP and AQP1 proteins, and it is mainly expressed at the apical membrane of the epithelial cells. These results suggest that the H₄ receptor is mainly expressed by resident renal cells of the loop of Henlé.

Discussion

Our results demonstrate for the first time that the H₄ histamine receptor is mainly expressed by cells of the loop of Henlé, and that this protein is significantly upregulated in the kidneys of diabetic animals, hence suggesting a possible role of the H₄ receptor in the pathogenesis of diabetes-associated renal disease.

Herein, we have reported the immunohistochemical identification the H₄ receptor in the kidney. The first observation of renal H₄ receptor expression dates back to its discovery in 2000 [18, 34-39]. In particular, RT-PCR experiments demonstrated the renal expression of the gene encoding for the H₄ receptor [36]. These data were not confirmed by Northern blot analysis, so it has been postulated that the H₄ receptor could be expressed by a minor cell population. Later, the constitutive, but very low H₄ receptor gene expression, was confirmed in different species [14-18, 36]; however, all these studies did not provide for the topological evaluation and cell type identification of the receptor. In contrast, our work was directed to assess the intra-renal distribution and levels of H₄ receptor. Consistently with previous studies, we measured, in control rats, H₄ receptor mRNA at the lower limit of detectability. This very low expression is in keeping with the weak positivity when immunohistochemistry evaluation was performed. Importantly, we observed that all diabetic animals with overt hyperglycemia (6 weeks after induction of diabetes), although did not meet the criteria for diabetic nephropathy, showed renal damage and expressed profoundly higher levels of H₄ receptors, thus suggesting a strong association between diabetes-associated renal damage and H₄ receptor overexpression. However, the present pilot study was only observational, and future work will focus on the functional consequences of the elevated levels of H₄ receptor and the respective regulatory mechanisms.

Previously, it has been shown that diabetic animals have a higher intra-renal histaminergic level [6, 7]. Moreover, parallel to the enhanced HDC enzyme activity [8], an increase in number and degranulation of mast cells was also demonstrated in the diabetic kidney [10-12]. The resulting higher histamine renal content was previously linked to the microvascular diabetes-associated changes in the glomerulus, where the expression of only H₁ and H₂ receptors was demonstrated [3, 13, 40]. However, all these studies were initiated prior to the discovery of the H₃ and H₄ receptors and were based on pharmacological characterization performed using dimaprit. This compound was initially characterized as a selective H₂ receptor agonist, but nowadays it has been found to act also on the H₄ receptor subtype, but with a much higher affinity [41]. Thus, these data suggest that a possible role of the H₄ receptor in mediating the renal effect of histamine could not be ruled out. Moreover, the discovery of H₁ and H₂ receptors only in the glomerulus led researchers to discard the hypothesis of a potential role for histamine in the tubules. Our findings, which demonstrate that the H₄ receptor subtype is absent in the glomeruli, but present in the tubules, leads us to revisit a tubular effect for histamine. This idea is in keeping with the presence of mast cells, not only in the periglomerular and perivascular area, but also in the tubulointerstitium and, occasionally, in the wall of atrophied tubules [12]. Thus, a possible role of histamine

released by mast cells and of the H₄ receptor in the tubular interstitium in promoting renal inflammation and fibrosis [11, 12] would be an intriguing hypothesis. Notably, the H₄ receptor is exquisitely sensitive to local histamine levels [42].

Another original contribution of our study is to provide an intra-nephron localization of the H₄ receptor. Colocalization experiments revealed that the H₄ receptor is expressed at the apical membrane of AQP1- and THP-positive cells, which are identified as epithelial cells of the loop of Henlé. This cellular localization suggests a possible role of the H₄ receptor distinct from the regulation of immune responses and inflammatory cell recruitment [43], leading us to hypothesize an active role of this receptor in modulating the loop of Henlé function(s), such as the transmembrane soluble transport processes. This study adds to the growing list of cell types expressing the H₄ receptor, subserving putative distinct roles to the other histamine receptors in the body, the latter including exocrine and endocrine functions in salivary glands [44] and the GI tract [25], respectively.

Collectively, these data provide compelling evidence for kidney H₄ expression and an anatomical basis which strongly suggests that the H₄ receptor could play a role in the onset/progression of diabetes-associated renal disease. Interestingly, although expression differences were observed among species [14, 15, 17, 18, 34], the similar tissue distribution in different mammals indicates conserved and comparable physiological roles of the H₄ receptor across species. Therefore, we could speculate similar roles in humans. On this basis, it is possible to hypothesize that our data on diabetic rats could have a positive translation to diabetic patients. However, whether this receptor has a compensatory or pathological implication remains to be established. In particular, understanding which effects an activation of H₄ receptor could exert on the loop of Henlé function is still to be resolved, and could represent the basis for proposing the renal H₄ receptor as a new potential pharmacological target for treating diabetes-associated renal disease.

Acknowledgments

This work was supported by Royal College of Anaesthesia/BJA, COST Action BM0806 (STSM hosted by the University of Durham) and the University of Turin. We are grateful to Dr Sara Castiglia, Dr Mara Rogazzo and Dr Alice Alfonso (Dipartimento di Scienza e Tecnologia del Farmaco, Università degli Studi di Torino) and Dr Stefania Bruno (Department of Internal Medicine, Centre for Molecular Biotechnology and Centre for Research in Experimental Medicine - CeRMS) for technical assistance.

Part of this study was presented at the 41st Annual Meeting of European Histamine Research Society held jointly with COST Action BM0806, May 2-5 2012, Belfast – Northern Ireland, UK and at the 48th EASD Annual Meeting Berlin, Germany, October 1-5 2012.

Conflict of interest

None.

Contribution statement

ACR, PLC and RF contributed to the conception and design of this study and **critically** reviewed the intellectual content of this manuscript. GM, CG and GC contributed to analysis and interpretation of immunohistochemistry. AP and DB contributed to analysis and interpretation of kidney morphometry. MAK contributed to the anti-H₄ receptor antibody supply and characterization. EB and MC contributed to perform the *in vivo* experiments. All authors contributed to the conception, design and drafting of this article and approved the final version of the article to be published.

Title and legends

Figure 1. Renal morphology assessed by PAS staining. Representative micrographs of kidney tissue from control rats (a, c) and diabetic animals (b, d). (a) Normal tubules. (b) Severe tubular degeneration with widespread epithelial cells loss, decreased PAS positivity of the brush-border membranes (arrows) and increased interstitial space (asterisks). (c) Normal glomerulus. (d) Glomerulus with capillary dilatation (arrowheads) and moderate mesangial matrix expansion (fibrillar and heterogeneous PAS-positive stained material). Original magnification 40X.

Figure 2. H₄ receptor expression: comparison between healthy and diabetic rats. (a) RT-PCR analysis of H₄ receptor kidney expression (12 rats/group). Pos= positive control (H₄ minigene), neg= negative control (water); (b) Quantitative RT-PCR analysis of H₄ receptor kidney expression. Data **were** normalized with 18S mRNA value. Results are the mean ± SEM for three independent experiments performed in duplicate. Data were analyzed by one-way analysis of variance (ANOVA) and the Student–Newman–Keuls test. **p* < 0.01 vs control.

Figure 3. H₄ receptor expression: comparison between healthy and diabetic rats. Representative micrographs of transverse kidney sections, immunolabelled with specific anti-H₄ receptor antibody. Original magnification 40X.

Figure 4. Quantitative assessment of H₄ receptor distribution in the kidney. Relative ratio of total H₄ positive staining area/total area as determined by color deconvolution. Results are the mean ± SEM of the OD (arbitrary units) of individual rats (ten images/zone) performed in duplicate. Data were analyzed by one-way analysis of variance (ANOVA) and the Student–Newman–Keuls test. **p* < 0.01 vs cortex and # *p* < 0.01 vs papilla.

Figure 5. H₄ receptor localization on the Loop of Henlé. Immunofluorescence stain showing colocalization of H₄ receptor with THP (a) and AQP1 (b) positive cells. Original magnification 40X.

References

1. Kondo S, Imamura I, Shinomura Y, Matsuzawa Y, Fukui H. Determination of histidine decarboxylase mRNA in various rat tissues by the polymerase chain reaction. *Inflamm Res* 1995; 44:111-5.
2. Morgan TK, Montgomery K, Mason V, West RB, Wang L, van de Rijn M, et al. Upregulation of histidine decarboxylase expression in superficial cortical nephrons during pregnancy in mice and women. *Kidney Int* 2006; 70:306-14.
3. Sedor JR, Abboud HE. Actions and metabolism of histamine in glomeruli and tubules of the human kidney. *Kidney Int* 1984; 26:144-52.
4. Beaven MA, Jacobsen S, Horakova Z. Modification of the enzymatic isotopic assay of histamine and its application to measurement of histamine in tissues, serum and urine. *Clin Chim Acta* 1972; 37:91-103.
5. Moore TC, Thompson DP, Glasscock RJ. Elevation in urinary and blood histamine following clinical renal transplantation. *Ann Surg* 1971; 173:381-8.
6. Gill DS, Thompson CS, Dandona P. Increased histamine in plasma and tissues in diabetic rats. *Diabetes Res* 1988; 7:31-4.
7. Markle RA, Hollis TM, Cosgarea AJ. Renal histamine increases in the streptozotocin-diabetic rat. *Exp Mol Pathol* 1986; 44:21-8.
8. Gill DS, Thompson CS, Dandona P. Histamine synthesis and catabolism in various tissues in diabetic rats. *Metabolism* 1990; 39:815-8.
9. Ichikawa I, Brenner BM. Mechanisms of action of histamine and histamine antagonists on the glomerular microcirculation in the rat. *Circ Res* 1979; 45:737-45.
10. Li Y, Liu FY, Peng YM, Li J, Chen J. Mast cell, a promising therapeutic target in tubulointerstitial fibrosis. *Med Hypotheses* 2007; 69:99-103.
11. Ruger BM, Hasan Q, Greenhill NS, Davis PF, Dunbar PR, Neale TJ. Mast cells and type VIII collagen in human diabetic nephropathy. *Diabetologia* 1996; 39:1215-22.
12. Zheng JM, Yao GH, Cheng Z, Wang R, Liu ZH. Pathogenic role of mast cells in the development of diabetic nephropathy: a study of patients at different stages of the disease. *Diabetologia* 2012; 55:801-11.
13. Torres VE, Northrup TE, Edwards RM, Shah SV, Dousa TP. Modulation of cyclic nucleotides in isolated rat glomeruli: role of histamine, carbamylcholine, parathyroid hormone, and angiotensin-II. *J Clin Invest* 1978; 62:1334-43.
14. Eisenschenk MN, Torres SM, Oliveira S, Been CS. The expression of histamine H₄ receptor mRNA in the skin and other tissues of normal dogs. *Vet Dermatol* 2011; 22:396-400.
15. Jiang W, Lim HD, Zhang M, Desai P, Dai H, Colling PM, et al. Cloning and pharmacological characterization of the dog histamine H₄ receptor. *Eur J Pharmacol* 2008; 592:26-32.
16. Liu C, Wilson SJ, Kuei C, Lovenberg TW. Comparison of human, mouse, rat, and guinea pig histamine H₄ receptors reveals substantial pharmacological species variation. *J Pharmacol Exp Ther* 2001; 299:121-30.
17. Oda T, Matsumoto S, Masuho Y, Takasaki J, Matsumoto M, Kamohara M, et al. cDNA cloning and characterization of porcine histamine H₄ receptor. *Biochim Biophys Acta* 2002; 1575:135-8.
18. Oda T, Matsumoto S, Matsumoto M, Takasaki J, Kamohara M, Soga T, et al. Molecular cloning of monkey histamine H₄ receptor. *J Pharmacol Sci* 2005; 98:319-22.
19. Ramagli LS. Quantifying protein in 2-D PAGE solubilization buffers. *Methods Mol Biol* 1999; 112:99-103.
20. Rosa AC, Rattazzi L, Miglio G, Collino M, Fantozzi R. Angiotensin II induces tumor necrosis factor- α expression and release from cultured human podocytes. *Inflamm Res* 2012.
21. Baumer W, Wendorff S, Gutzmer R, Werfel T, Dijkstra D, Chazot P, et al. Histamine H₄ receptors modulate dendritic cell migration through skin--immunomodulatory role of histamine. *Allergy* 2008; 63:1387-94.
22. Dijkstra D, Leurs R, Chazot P, Shenton FC, Stark H, Werfel T, et al. Histamine downregulates monocyte CCL2 production through the histamine H₄ receptor. *J Allergy Clin Immunol* 2007; 120:300-7.
23. Dijkstra D, Stark H, Chazot PL, Shenton FC, Leurs R, Werfel T, et al. Human inflammatory dendritic epidermal cells express a functional histamine H₄ receptor. *J Invest Dermatol* 2008; 128:1696-703.
24. Grandi D, Shenton FC, Chazot PL, Morini G. Immunolocalization of histamine H₃ receptors on endocrine cells in the rat gastrointestinal tract. *Histol Histopathol* 2008; 23:789-98.
25. Morini G, Becchi G, Shenton FC, Chazot PL, Grandi D. Histamine H₃ and H₄ receptors are expressed on distinct endocrine cell types in the rat fundic mucosa. *Inflamm Res* 2008; 57 Suppl 1:S57-8.
26. van Rijn RM, Chazot PL, Shenton FC, Sansuk K, Bakker RA, Leurs R. Oligomerization of recombinant and endogenously expressed human histamine H₄ receptors. *Mol Pharmacol* 2006; 70:604-15.
27. van Rijn RM, van Marle A, Chazot PL, Langemeijer E, Qin Y, Shenton FC, et al. Cloning and characterization of dominant negative splice variants of the human histamine H₄ receptor. *Biochem J* 2008; 414:121-31.
28. Chazot PL, Reiss C, Chopra B, Stephenson FA. [3H]MDL 105,519 binds with equal high affinity to both assembled and unassembled NR1 subunits of the NMDA receptor. *Eur J Pharmacol* 1998; 353:137-40.

29. Chazot PL, Hann V, Wilson C, Lees G, Thompson CL. Immunological identification of the mammalian H₃ histamine receptor in the mouse brain. *Neuroreport* 2001; 12:259-62.
30. Connelly WM, Shenton FC, Lethbridge N, Leurs R, Waldvogel HJ, Faull RL, et al. The histamine H₄ receptor is functionally expressed on neurons in the mammalian CNS. *Br J Pharmacol* 2009; 157:55-63.
31. Thompson CL, Drewery DL, Atkins HD, Stephenson FA, Chazot PL. Immunohistochemical localization of N-methyl-D-aspartate receptor NR1, NR2A, NR2B and NR2C/D subunits in the adult mammalian cerebellum. *Neurosci Lett* 2000; 283:85-8.
32. Ruifrok AC, Johnston DA. Quantification of histochemical staining by color deconvolution. *Anal Quant Cytol Histol* 2001; 23:291-9.
33. Ruifrok AC, Katz RL, Johnston DA. Comparison of quantification of histochemical staining by hue-saturation-intensity (HSI) transformation and color-deconvolution. *Appl Immunohistochem Mol Morphol* 2003; 11:85-91.
34. Liu C, Ma X, Jiang X, Wilson SJ, Hofstra CL, Blevitt J, et al. Cloning and pharmacological characterization of a fourth histamine receptor H₄ expressed in bone marrow. *Mol Pharmacol* 2001; 59:420-6.
35. Morse KL, Behan J, Laz TM, West RE, Jr., Greenfeder SA, Anthes JC, et al. Cloning and characterization of a novel human histamine receptor. *J Pharmacol Exp Ther* 2001; 296:1058-66.
36. Nakamura T, Itadani H, Hidaka Y, Ohta M, Tanaka K. Molecular cloning and characterization of a new human histamine receptor, HH4R. *Biochem Biophys Res Commun* 2000; 279:615-20.
37. Nguyen T, Shapiro DA, George SR, Setola V, Lee DK, Cheng R, et al. Discovery of a novel member of the histamine receptor family. *Mol Pharmacol* 2001; 59:427-33.
38. Oda T, Morikawa N, Saito Y, Masuho Y, Matsumoto S. Molecular cloning and characterization of a novel type of histamine receptor preferentially expressed in leukocytes. *J Biol Chem* 2000; 275:36781-6.
39. Zhu Y, Michalovich D, Wu H, Tan KB, Dytko GM, Mannan IJ, et al. Cloning, expression, and pharmacological characterization of a novel human histamine receptor. *Mol Pharmacol* 2001; 59:434-41.
40. Wilson CB, Gushwa LC, Peterson OW, Tucker BJ, Blantz RC. Glomerular immune injury in the rat: effect of antagonists of histamine activity. *Kidney Int* 1981; 20:628-35.
41. Lim HD, Adami M, Guaita E, Werfel T, Smits RA, de Esch IJ, et al. Pharmacological characterization of the new histamine H₄ receptor agonist VUF 8430. *Br J Pharmacol* 2009; 157:34-43.
42. Thurmond RL, Gelfand EW, Dunford PJ. The role of histamine H₁ and H₄ receptors in allergic inflammation: the search for new antihistamines. *Nat Rev Drug Discov* 2008; 7:41-53.
43. Zampeli E, Tiligada E. The role of histamine H₄ receptor in immune and inflammatory disorders. *Br J Pharmacol* 2009; 157:24-33.
44. Stegaev V ST, Porola P, Mieliauskaite D, Rotar Z, Mackiewicz Z, Stark H, Chazot PL, Konttinen YT. First Identification of the Histamine₄ Receptors (H₄R) in Healthy Salivary Glands and in Focal Sialadenitis in Sjögren's Syndrome. *Arthritis Rheum* 2012; 64:-.

Figure 1_Rosa et al.

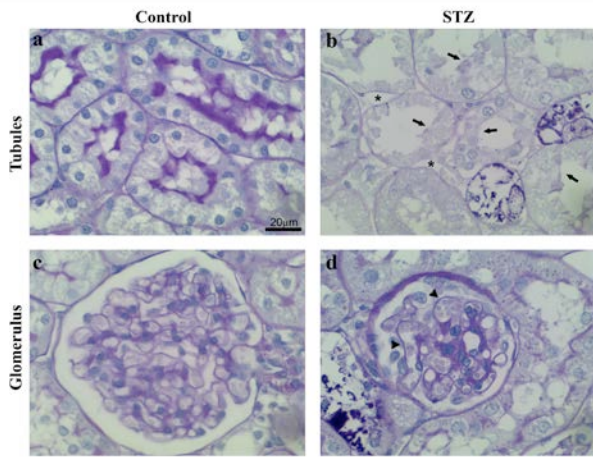


Figure 2_Rosa et al.

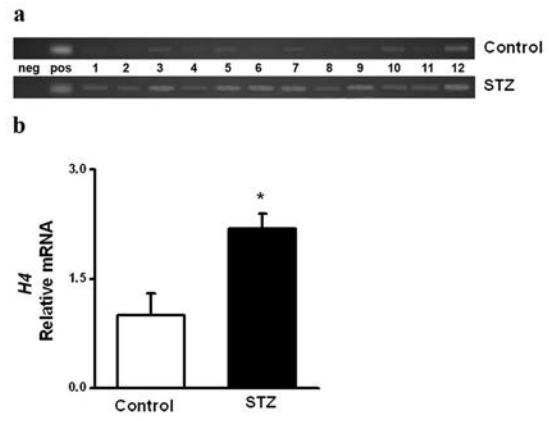
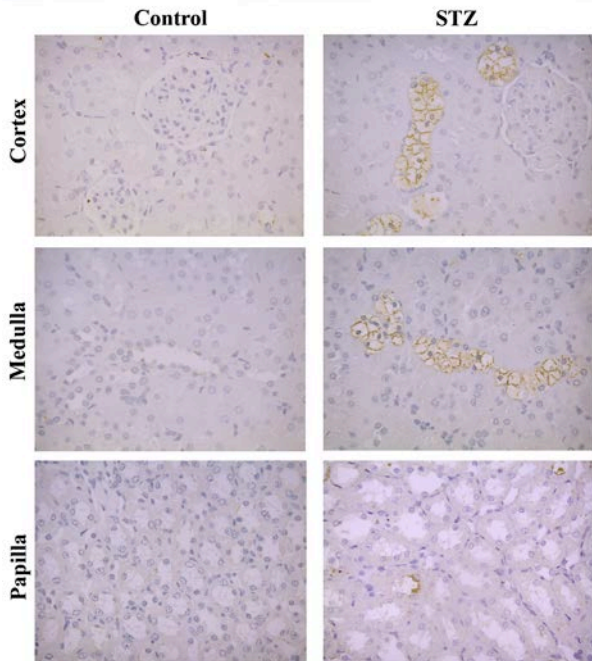
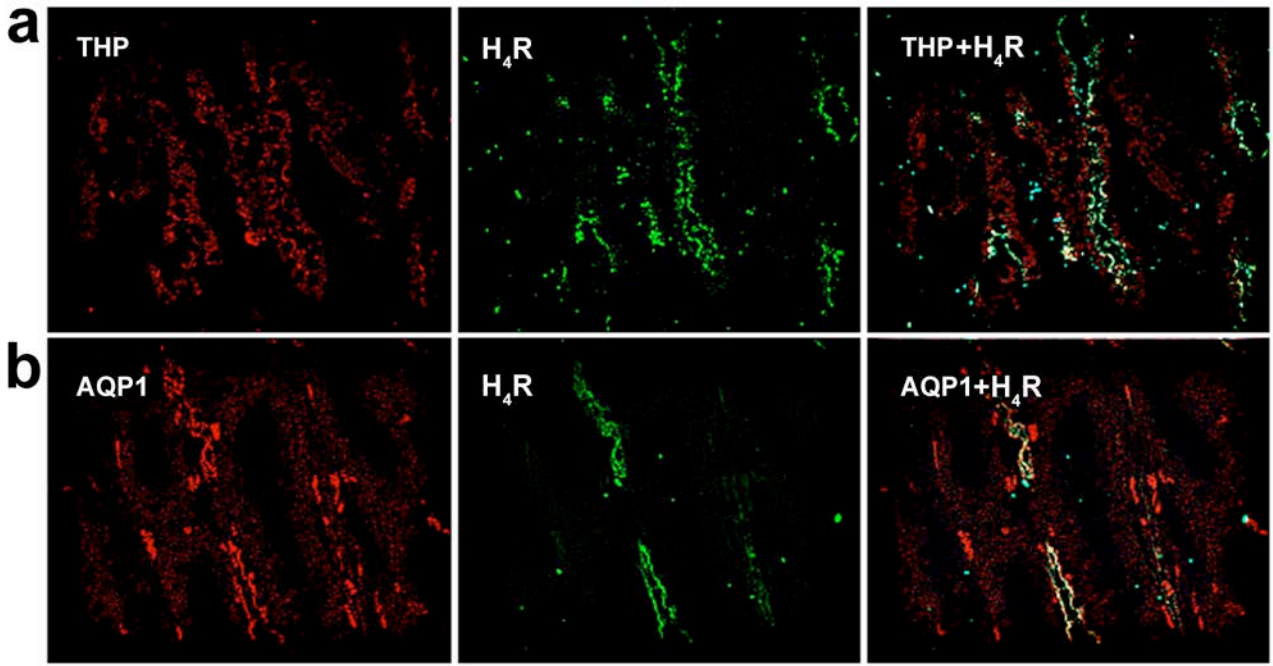
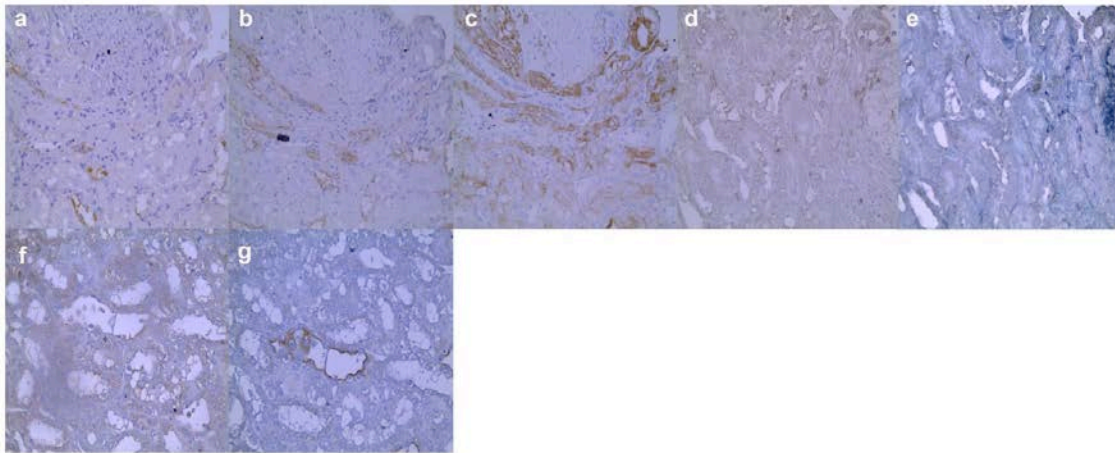


Figure 3_Rosa et al.





Rosa et al_Supplementary Materials



H₄ receptor localization in the medulla. Representative micrographs of transverse sequential kidney sections immunolabeled with specific anti-H₄ receptor antibody (a,f), Tamm-Horsfall glycoprotein (b), Aquaporin 1 (c), Tissue non-specific alkaline phosphatase (d), Na-K-Cl cotransporter 1 (e) or Aquaporin 2 (f). Original magnification 40X