

AperTO - Archivio Istituzionale Open Access dell'Università di Torino

**Heterozygous deletion of KLHL1/ATX80S at the SCA8 locus is unlikely associated with cerebellar impairment in humans**

**This is the author's manuscript**

*Original Citation:*

*Availability:*

This version is available <http://hdl.handle.net/2318/1521986> since 2016-07-26T09:22:47Z

*Published version:*

DOI:10.1007/s12311-015-0679-3

*Terms of use:*

Open Access

Anyone can freely access the full text of works made available as "Open Access". Works made available under a Creative Commons license can be used according to the terms and conditions of said license. Use of all other works requires consent of the right holder (author or publisher) if not exempted from copyright protection by the applicable law.

(Article begins on next page)



# UNIVERSITÀ DEGLI STUDI DI TORINO

***This is an author version of the contribution published on:***

*Questa è la versione dell'autore dell'opera:*

*[Cerebellum. 2016 Apr;15(2):208-12. doi: 10.1007/s12311-015-0679-3]*

***The definitive version is available at:***

*La versione definitiva è disponibile alla URL:*

*[<http://link.springer.com/article/10.1007%2Fs12311-015-0679-3>]*

Heterozygous deletion of *KLHL1/ATX8OS* at the SCA8 locus is unlikely associated with cerebellar impairment in humans.

Giorgia Mandrile <sup>1,2</sup>, Eleonora Di Gregorio <sup>3,4</sup>, Himanshu Goel <sup>5</sup>, Daniela Giachino <sup>1,2</sup>, Stefania De Mercanti <sup>2,6</sup>, Marco Iudicello <sup>6</sup>, Marco Rolando <sup>7</sup>, Sabrina Losa <sup>7</sup>, Mario De Marchi <sup>1,2</sup>, Alfredo Brusco <sup>3,4</sup>

<sup>1</sup> San Luigi University Hospital, Medical Genetics, Orbassano, 10043, Italy

<sup>2</sup> University of Torino, Department of Clinical & Biological Sciences, Orbassano, 10043, Italy

<sup>3</sup> University of Torino, Department of Medical Sciences, 10126, Italy

<sup>4</sup> Città della Salute e della Scienza University Hospital, Medical Genetics, Torino, 10126, Italy

<sup>5</sup> University of Newcastle, Faculty of Health and Medicine, Callaghan and Hunter Genetics, Waratah, New South Wales, NSW2308, Australia

<sup>6</sup> San Luigi Gonzaga University Hospital, Neurology Division, Orbassano, 10043, Italy

<sup>7</sup> Azienda Sanitaria Locale TO3 di Collegno e Pinerolo, Neuropsichiatria Infantile, Collegno, 10093, Italy

Corresponding author: Alfredo Brusco, University of Torino, Department of Medical Sciences, via Santena 19, 10126, Torino, Italy. Fax +390116706582; e-mail: [alfredo.brusco@unito.it](mailto:alfredo.brusco@unito.it)

**Keywords:** *ATXNOS8*, *KLHL1*, SCA8, genomic deletion, ataxia

**Conflict of interest:** The authors declare no conflict of interest

## **ABSTRACT**

Spinocerebellar ataxia type 8 is a dominantly inherited ataxia, mainly occurring in adulthood. It is caused by a CTG.CAG tract expansion in the *ATXN8OS* gene, an untranslated antisense transcript that partially overlaps the *KLHL1* gene.

We report two families, each composed of one parent and one son/daughter, segregating a small genomic deletion spanning only *ATXN8OS* gene and part of *KLHL1*. Both probands were referred for speech and articulation difficulties, and one had mild intellectual disability. The deletion was inherited from a healthy parent. Neither of the probands had signs of cerebellar dysfunction. MRI performed on two subjects of family 1 did not show brain anomalies. In contrast with the *KLHL1/ATXN8OS* knockout mouse model, our data suggests that heterozygous deletion in *KLHL1/ATXN8OS* is unlikely to be associated with ataxia/cerebellar involvement in humans, although it may contribute to speech/articulation problems or neuropsychiatric symptoms other than cerebellar/ataxia.

## INTRODUCTION

Spinocerebellar ataxia type 8 (SCA8)(MIM 608768) is a dominantly inherited ataxia typically occurring in adulthood, with onset of the disease that may range from age one to 65 years [1-6]. Common initial symptoms are scanning dysarthria with a characteristic drawn-out slowness of speech and gait instability. Some individuals present with nystagmus, dysmetric saccades and, occasionally ophthalmoplegia. Hyperreflexia and extensor plantar responses are present in some severely affected individuals. Life span is typically not shortened.

SCA8 is caused by repeat expansions initially thought to involve a non-coding CTG tract in the *ATXN8OS* gene - formerly known as *SCA8* (MIM 603680) - an untranslated antisense transcript partially overlapping the Kelch-like 1 gene (*KLHL1*) (MIM 605332) [7]. The CTG repeat was later found to be transcribed also in the opposite direction as (CAG)<sub>n</sub> repeat in the *ATXN8* gene, encoding a nearly pure polyglutamine protein [8].

An RNA toxic effect of the CUG expanded repeats has been suggested, together with the possibility of non-ATG translation (RAN translation) which occurs across long, hairpin-forming repeats and results in the accumulation of potentially toxic SCA8 polyalanine [9, 10].

The (CTG.CAG)<sub>n</sub> repeat length most often associated with ataxia ranges from 80 to 250. However, repeats from 71 to more than 1,300 have been occasionally found in individuals with ataxia. The disease is characterized by a reduced penetrance most often with alleles of fewer than 100 repeats. We report two unrelated families with genomic deletions completely overlapping *ATXN8OS* gene and great part of *KLHL1* gene. These deletions were present in a healthy parent in both families. A total of four subjects with *ATXN8OS/KLHL1* genes deletion could be studied and did not show any cerebellar symptoms or MRI changes in cerebellum.

## MATERIALS AND METHODS

### *Patients*

Probands were identified during diagnostic array-CGH exams performed at the Medical Genetics Unit of the “Città della salute e della Scienza” University Hospital and Hunter Genetics, Waratah, New South Wales, Australia.

The proband of family 1 (Decipher code: DGT283337) had an initial diagnosis of intellectual disability. She had normal karyotype and *FMR1* expansion. Proband of family 2 (Decipher code: DGT278559) presented with speech delay only. He had normal *FMR1* expansion. Both patients had normal urine metabolic screen, and purine and pyrimidine metabolites.

### *Array-CGH*

Genomic DNA was extracted from peripheral blood cells using standard procedures (Qiagen, Mannheim, Germany). Array-CGH was performed on probands of both families using an 8x60k whole-genome oligonucleotide array (Agilent Technologies, Santa Clara, California, USA) or the Cytochip ISCA 8x60k array (Bluegenome) as per manufacturer’s instructions. Data were analyzed with Agilent CGH analytics software (ver.4.0.81) or Bluemulti v2.4 software. Reference human genomic DNA was GRCh37/hg19.

Deletions were verified in proband of family 1 using real-time quantitative PCR (conditions available upon request). Deletion was confirmed in family 2 using FISH probes.

### *Clinical and Magnetic resonance imaging (MRI)*

Routine neurological exams were performed on the probands and the parent carrying the deletion. Magnetic resonance Imaging (MRI) was performed using a 1.5 Tesla apparatus with T1, T2 and FLAIR sequences acquisition.

## **RESULTS**

### *Family 1. Phenotype*

Case DGT283337 (Figure 1) was the third daughter of healthy non-consanguineous parents; her siblings were healthy with normal intellectual abilities. Family history was unremarkable. The patient was referred for genetic assessment at 10 years of age for problems in speech and sentence structure. She was born via a normal delivery at 32 weeks of gestation after an uneventful pregnancy. Her birth weight was 3,580 g (90-97<sup>th</sup> centile, according to the Italian growth curves), birth length was 53cm (90-97<sup>th</sup> centile) and her head circumference was not reported. She had a normal review of systems. She walked without any assistance at 17 months. Lallation began at 8 months of age. Speech difficulties were reported at about 4 years and improved after therapy. On neuropsychiatric evaluation, short attention span was noted; no motor abnormalities or other neurological signs were reported. Cognitive evaluation (WISC-III scale) demonstrated a mild intellectual deficit (IQ: 62; verbal IQ: 54, Performance IQ: 79). Brain MRI (Figure 2 A-D), eye examination, abdomen and heart ultrasounds were normal.

Her growth parameters at 9 years were between 50-75<sup>th</sup> percentile (height: 137 cm, weight: 33 kg, head circumference: 55 cm). She did not have a significant dysmorphism.

Her father who is now 59 years old was the only child of non-consanguineous parents. He has reported subjective sensation of instability of posture in last few years, but his neurological examination was normal. He underwent a neurological examination - including assessment through the International Cooperative Ataxia Rating Scale (ICARS)- and it revealed no abnormal gait or dysarthria, normal muscle tone and strength, coordination, sensitivity, reflexes and cranial nerves function (in particular oculomotor dysfunction and nystagmus have been excluded). Brain MRI showed several areas of gliosis in the frontal white matter; no cerebellar alterations were reported (Figure 2 E-H). Auditory evoked potentials were normal; cognitive evaluation demonstrated a short attention span.

*Molecular data and databases mining*

Array-CGH analysis revealed two paternally inherited rearrangements in the proband: a 4 Mb duplication at 8q13.33q21.11 and a 800 kb deletion at 13q21.33 (Figure 1A, B). The 8q duplication was also transmitted to proband's one brother who is healthy and with an above average intelligence. The 13q deletion was absent in proband's siblings (Figure 1A).

The 8q duplication spans from 72,268,801 (normal probe) to 72,340,784 (first duplicated probe), and 76,149,340 (last duplicated probe) to 76,311,849 (normal probe) (GRCh37/hg19).

The 13q deletion spans from 70,370,848 (first deleted probe) to 71,062,600 (last deleted probe) (GRCh37/hg19). In this deleted region part of *KLHL1* and the entire *ATXOS8* genes were involved.

A search for copy number variations (CNVs) in the 8q and 13q regions surrounding the *KLHL1* and *ATXN8OS* genes was performed in Decipher (<https://decipher.sanger.ac.uk>),

ISCA(<http://www.iscaconsortium.org>) and Database of Genomic Variants (DGV;

<http://dgv.tcag.ca/dgv/app/home>) databases.

Several duplications / deletions overlapped our 8q duplication: all were large rearrangements associated with complex phenotypes (whenever described); only two larger duplications are reported in DGV database.

Fourteen rearrangements reported in Decipher (V.7.0) overlapped the 13q21.33 deleted region: four duplications and ten deletions; most cases were large rearrangements between 1-20 Mb, in size with the exception of case DGT278559 described below. Several CNVs are reported, all smaller than ours.

### *Family 2. Phenotype and molecular data*

Case DGT278559 was a 4 years old boy, came to clinic for an assessment for mild expressive language delay and difficulties in articulation. His parents reported a normal prenatal and birth history, and normal growth and motor milestones acquisition. His general health has also been satisfactory. Speech improved significantly after one year of therapy. His height was 114.5 cm



(>97th centile), weight was 20.5 kg (97th centile) and his head circumference was 52.1 cm (50-98th centile). He did not have significant dysmorphic features or major/minor malformations. His cognitive evaluation was reported to be normal. He never underwent a brain MRI. His both siblings are healthy. The 13q deletion was inherited from his mother who does not have speech problems. She has above average intelligence. She had no sign of neurological involvement and never had a brain MRI.

Array-CGH in the proband showed a maternally inherited 357 kb deletion at 13q21.33 (Figure 1). The 13q deletion spans from 70,486,026 to 70,843,210 (GRCh37/hg19). In this region part of *KLHL1* and the entire *ATXOS8* genes were involved.

## **DISCUSSION**

SCA8 is a genetically complex autosomal dominant cerebellar ataxia with incomplete penetrance and variable expressivity. A mouse model, in which SCA8 BAC- expansion developed a progressive neurological phenotype, demonstrated the pathogenicity of the (CTG.CAG)<sub>n</sub> expansion [8]. However, the role of the (CTG.CAG)<sub>n</sub> repeat in the disease remained unclear. Mice heterozygous or homozygous for the *Klh1l* deletion showed significant gait abnormalities, progressive loss of motor coordination, and Purkinje cell dendritic deficits [7]. These data suggested that loss of proper expression from even a single *KLHL1* allele would be sufficient to cause ataxia in humans, and that pathogenic SCA8 expansions may cause the disease through a loss of *KLHL1* activity in Purkinje cells.

We report two families with a similar genomic deletion in heterozygous state involving only *ATXN8OS* and *KLHL1* genes. In both cases, the deletion segregated from an unaffected parent. Proband of family 1 (III.3) arrived at our observation for a mild cognitive impairment. She showed two different genomic unbalances, a large duplication of 4 Mb on chromosome 8 and a deletion of 700 kb on chromosome 13. These chromosomal changes were paternally inherited and not reported

in the literature. Her father did not show any pathological sign both on clinical neurologic examination and brain MRI. The 8q duplication involves at least 23 genes, none of which is associated with a dominantly inherited disease. Decipher V7.0 haploinsufficiency index suggests that three genes are dosage sensitive (*EYA1*, *PII5*, *ZFHX4*). We studied proband's siblings and showed that the duplication is shared by her unaffected brother (III.2). His medical history did not reveal any sign or symptom of neurologic disease, and he had normal intelligence. This strongly suggests that this rearrangement is unlikely to be associated to a pathological phenotype, even if it is a large (~4 Mb) and gene rich.

The deletion on chromosome 13 drew our attention because it contained the SCA8 region. However, no sign of cerebellar involvement, both clinically and neuroradiologically, was present either in the father (age 59 yr) or his daughter (age 9 yr). Paternal grandparents were also reported healthy. Also in proband of family 2, affected by mild speech delay, the deletion involving only *KLHL1* and *ATXN8OS* genes is inherited from a healthy mother, who did not have any neurological impairment.

Although limited to two small families, our data suggest that *KLHL1/ATXN8OS* deletion in heterozygosis is unlikely to be associated with ataxia/cerebellar involvement. We hypothesize that SCA8 expansion is not merely causing a simple loss of function of *KLHL1*, contrary to what was suggested by the knockout mouse model [12]. Other pathogenic mechanisms (toxic effect of expanded (CUG)<sub>n</sub> tract at RNA level, toxic effect of the CAG-encoded polyglutamine, or potentially toxic polyalanine derived from RAN translation) may have a primary role in the disease even in combined effects [10].

On the other hand, we cannot exclude the possibility that *ATXN8OS* or *KLHL1* haploinsufficiency may have a role in brain development or contribute to speech/articulation problems or neuropsychiatric symptoms other than cerebellar/ataxia. This may be related to the mild intellectual disability and short attention span, respectively in proband of family 1 and her father. Also speech

difficulties, reported in both probands may possibly be related to functional alterations of *KLHL1/ATX8OS*.

Our findings, suggest further studies are needed to clarify the effect of *KLHL1/ATX8OS* deletion in humans.

## ACKNOWLEDGMENTS

This work was funded by PRIN 2010\_2011 project 20108WT59Y, Associazione Italiana Sindromi Atassiche (AISA), and Associazione E.E. Rulfo per la Genetica Medica (to A Brusco). We thank Dr. Elena Gaidolfi for providing MRI brain scans.

## FIGURE LEGENDS

**Figure 1. Family trees and array-CGH analyses.** A. Pedigrees of families 1 and 2. Probands are indicated with an arrow. Segregation of rearrangements are reported in available members of the families. B. Array-CGH results showed two rearrangements on 8q and 13q in III.3, family 1, and a 13q deletion in III.2, family 2. On the X-axis, the log ratio is reported ( $\log_2$  intensity of (Cy5 fluorochrome/Cy3 fluorochrome)). Expected values are from -0.7 to -1 for a deletion (green dots), 0 for normal (black dots), and +0.5 to +1 for a duplication (red dots). Array nomenclature is reported below aCGH panels. C. Detail of the region involved the two rearrangements with cytogenetic bands and gene names (Database of Genomics variants)[13]. Below, red bars indicate the two genomic deletions at chromosome 13q (patients DGT283337, DGT278559)(Decipher database)[14]. In both cases, *ATXN8OS* and *KLHL1* are the only genes disrupted in the deleted region.

**Figure 2. Brain MRI scans.** A-D. Patient DGT283337 (Family 1, III.1) showed a normal cerebellar development. T1-weighted mid-sagittal (A) and transverse (B). Coronal T2-

weighted view (C) and transverse T2-weighted view (D). E-H. Proband father (Family 1, II.1). MRI revealed several areas of gliosis in the frontal white matter compatible with age. No cerebellar alterations were reported. Mid-sagittal (E) and transverse (F) T1-weighted views. Dual coronal views (G-H).

## REFERENCES

1. M. D. Koob, M. L. Moseley, L. J. Schut, K. A. Benzow, T. D. Bird, J. W. Day et al. An untranslated CTG expansion causes a novel form of spinocerebellar ataxia (SCA8). *Nat Genet* 1999;21:379-84
2. E. Cellini, B. Nacmias, P. Forleo, S. Piacentini, B. M. Guarnieri, A. Serio et al. Genetic and clinical analysis of spinocerebellar ataxia type 8 repeat expansion in Italy. *Arch Neurol* 2001;58:1856-9
3. J. W. Day, L. J. Schut, M. L. Moseley, A. C. Durand and L. P. Ranum. Spinocerebellar ataxia type 8: clinical features in a large family. *Neurology* 2000;55:649-57
4. Y. Ikeda, M. Shizuka-Ikeda, M. Watanabe, M. Schmitt, K. Okamoto and M. Shoji. Asymptomatic CTG expansion at the SCA8 locus is associated with cerebellar atrophy on MRI. *J Neurol Sci* 2000;182:76-9
5. M. J. Sobrido, J. A. Cholfín, S. Perlman, S. M. Pulst and D. H. Geschwind. SCA8 repeat expansions in ataxia: a controversial association. *Neurology* 2001;57:1310-2
6. B. Tazon, C. Badenas, L. Jimenez, E. Munoz and M. Mila. SCA8 in the Spanish population including one homozygous patient. *Clin Genet* 2002;62:404-9
7. J. P. Nemes, K. A. Benzow, M. L. Moseley, L. P. Ranum and M. D. Koob. The SCA8 transcript is an antisense RNA to a brain-specific transcript encoding a novel actin-binding protein (KLHL1). *Hum Mol Genet* 2000;9:1543-51
8. M. L. Moseley, T. Zu, Y. Ikeda, W. Gao, A. K. Mosemiller, R. S. Daughters et al. Bidirectional expression of CUG and CAG expansion transcripts and intranuclear polyglutamine inclusions in spinocerebellar ataxia type 8. *Nat Genet* 2006;38:758-69
9. J. D. Cleary and L. P. Ranum. Repeat-associated non-ATG (RAN) translation in neurological disease. *Hum Mol Genet* 2013;22:R45-51
10. T. Zu, B. Gibbens, N. S. Doty, M. Gomes-Pereira, A. Huguet, M. D. Stone et al. Non-ATG-initiated translation directed by microsatellite expansions. *Proc Natl Acad Sci U S A* 2011;108:260-5
11. K. J. Livak and T. D. Schmittgen. Analysis of relative gene expression data using real-time quantitative PCR and the 2(-Delta Delta C(T)) Method. *Methods* 2001;25:402-8
12. Y. He, T. Zu, K. A. Benzow, H. T. Orr, H. B. Clark and M. D. Koob. Targeted deletion of a single Sca8 ataxia locus allele in mice causes abnormal gait, progressive loss of motor coordination, and Purkinje cell dendritic deficits. *J Neurosci* 2006;26:9975-82
13. J. R. Macdonald, R. Ziman, R. K. Yuen, L. Feuk and S. W. Scherer. The Database of Genomic Variants: a curated collection of structural variation in the human genome. *Nucleic Acids Res* 2014;42:D986-92
14. H. V. Firth, S. M. Richards, A. P. Bevan, S. Clayton, M. Corpas, D. Rajan et al. DECIPHER: Database of Chromosomal Imbalance and Phenotype in Humans Using Ensembl Resources. *Am J Hum Genet* 2009;84:524-33

Figure 1

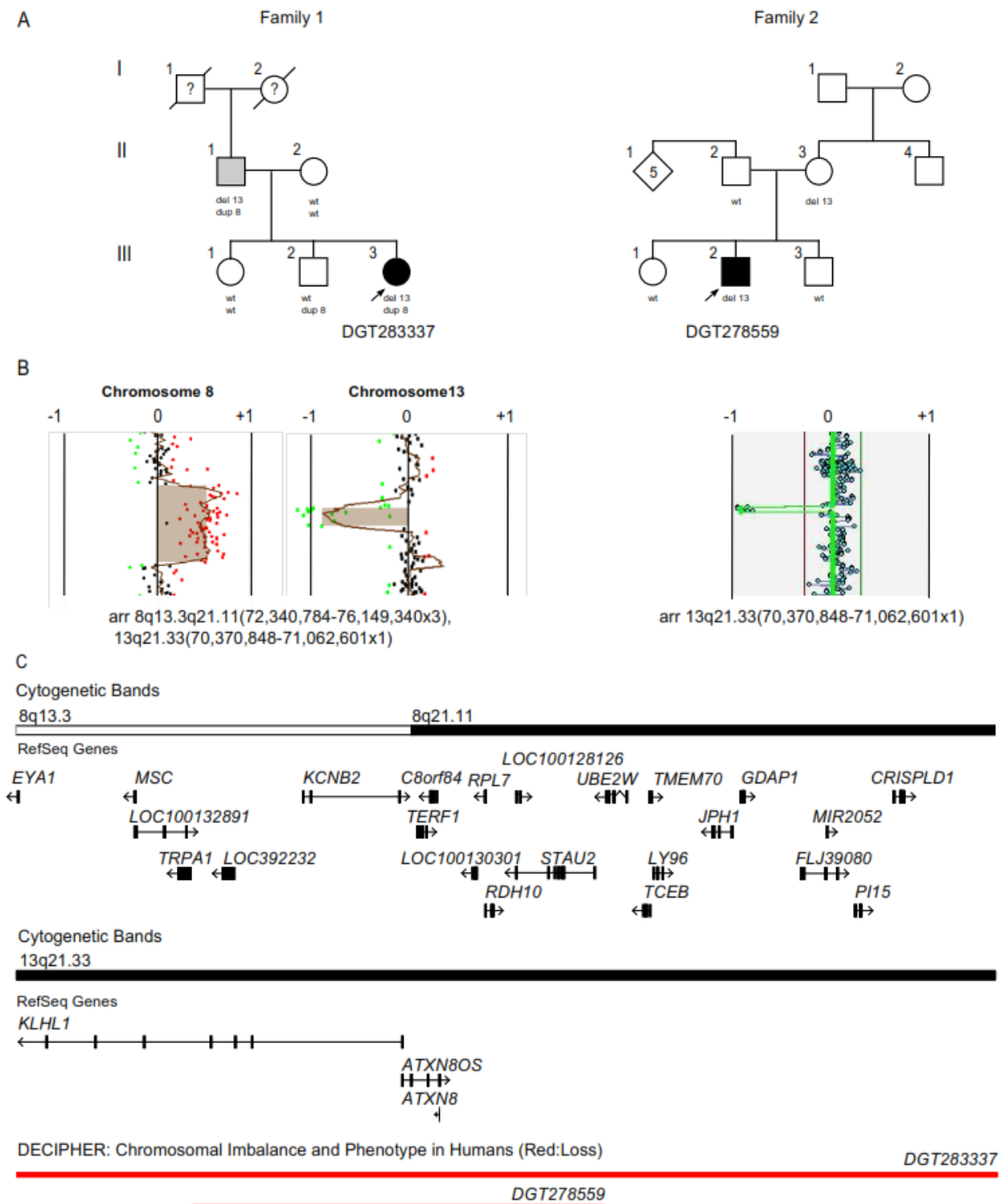


Figure 2

